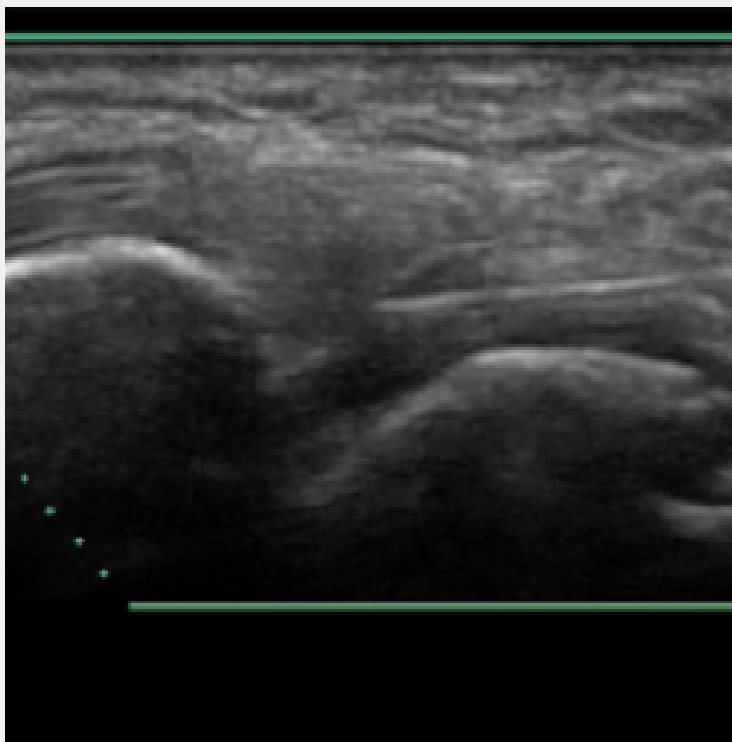
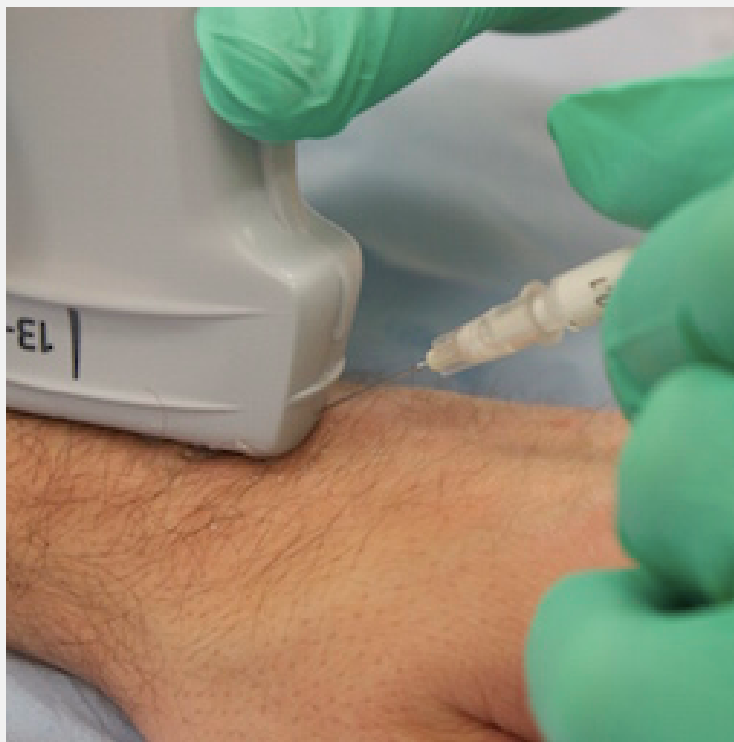



Ultrasound guided injection Wrist injection



Patient position: Sitting

Arm position: Pronated, wrist flexed

Ultrasound: Visualise the dorsal recess of the radiocarpal joint adjacent to Listers tubercle.

Injection technique: In plane technique from distal to proximal, ensuring the needle tip is visualised in the joint recess.

Suggested needle: Blue 23G

The information is not intended as professional or other advice. Nor is it intended to be a substitute for possession of an appropriate level of training, qualifications, skill and experience in the matters covered. You rely on such information at your own risk.

